

## Arrhythmogenic Right Ventricular Dysplasia/Cardiomyopathy Associated with Mutations in the Desmosomal Gene Desmocollin-2

Petros Syrris, Deirdre Ward, Alison Evans, Angeliki Asimaki, Estelle Gandjbakhch, Srijita Sen-Chowdhry, and William J. McKenna

Arrhythmogenic right ventricular dysplasia/cardiomyopathy (ARVD/C) is an inherited myocardial disorder associated with arrhythmias, heart failure, and sudden death. To date, mutations in four genes encoding major desmosomal proteins (plakoglobin, desmoplakin, plakophilin-2, and desmoglein-2) have been implicated in the pathogenesis of ARVD/C. We screened 77 probands with ARVD/C for mutations in desmocollin-2 (*DSC2*), a gene coding for a desmosomal cadherin. Two heterozygous mutations—a deletion and an insertion—were identified in four probands. Both mutations result in frameshifts and premature truncation of the desmocollin-2 protein. For the first time, we have identified mutations in desmocollin-2 in patients with ARVD/C, a finding that is consistent with the hypothesis that ARVD/C is a disease of the desmosome.

Arrhythmogenic right ventricular dysplasia/cardiomyopathy (ARVD/C [MIM #107970]) is an inherited myocardial disorder associated with ventricular arrhythmias, heart failure, and sudden death.<sup>1,2</sup> The main pathologic characteristic of ARVD/C is loss of myocardium, predominately in the right ventricle, and its replacement with adipose and fibrous tissue.<sup>3</sup> Familial ARVD/C is believed to account for at least 30%–50% of all cases,<sup>4</sup> although penetrance in some families is estimated to be <30%.<sup>5</sup>

To date, six genes have been implicated in the pathogenesis of the disease. Four of them—plakoglobin, desmoplakin, plakophilin-2, and desmoglein-2—encode major desmosomal proteins,<sup>6–17</sup> a fact that indicates that ARVD/C may be a disease of cell adhesion. A recessive mutation in plakoglobin was found in Naxos disease, a syndrome of ARVD/C, with phenotypes palmoplantar keratoderma and woolly hair.<sup>6</sup> Dominant mutations in desmoplakin have been shown to cause ARVD/C,<sup>7–9</sup> whereas recessive mutations in this gene have been reported in cases of combined phenotypes of cardiomyopathy and skin/hair abnormalities.<sup>10,11</sup> A large number of disease-causing mutations have been identified for plakophilin-2, which suggests that this gene plays a major role in the pathogenesis of ARVD/C.<sup>12–15</sup> Recent studies have reported mutations in a fourth desmosomal gene, desmoglein-2 (*DSG2*), in familial cases of ARVD/C.<sup>16,17</sup>

In addition, two nondesmosomal genes have been associated with specific types of ARVD/C: patients with catecholaminergic polymorphic ventricular tachycardia have mutations in the cardiac ryanodine receptor gene (*ARVD2*),<sup>18,19</sup> and transforming growth factor  $\beta 3$  has been proposed as the disease gene in ARVD1.<sup>20</sup> Desmosomes are adhesive cell-cell junctions in epithelia and cardiac muscle

that anchor the intermediate filament cytoskeleton to the cytoplasmic membrane.<sup>21</sup> In addition to providing tissues with structural strength, desmosomes also participate in morphogenesis and differentiation.<sup>21</sup> Proteins belonging to three main families are found in desmosomes: plakins, armadillo repeat proteins, and cadherins.

Desmosomal cadherins, desmocollins, and desmogleins are type I membrane glycoproteins responsible for mediating adhesion.<sup>22</sup> In humans, there are three desmocollin isoforms (*DSC1–3*) that are encoded by genes clustered on chromosome 18. Of them, *DSC2* is ubiquitously expressed in desmosomal tissues, and it appears to be the only desmocollin isoform present in cardiac tissue.<sup>23</sup> *DSC2*, like classic cadherins, contains five extracellular domains at the amino terminus, a single transmembrane-spanning domain, and a cytoplasmic tail at the carboxy terminus.<sup>24</sup> *DSC2* is found in two variants, which are produced by alternate splicing of exon 16.<sup>24</sup> Desmocollins bind to desmogleins through their extracellular domains in a  $\text{Ca}^{2+}$ -dependent manner,<sup>25</sup> whereas their cytoplasmic domains have binding sites for plakoglobin.<sup>26</sup>

There have been reports of *DSG2* mutations in patients with ARVD/C,<sup>16,17</sup> and desmocollin-2 remains the only major desmosomal protein expressed in cardiac tissue that has not yet been implicated in the pathogenesis of the disorder. Since *DSC2* represents a plausible candidate gene for ARVD/C, we screened 77 consecutive white patients who received the diagnosis of ARVD/C (who were free of mutations in plakoglobin, desmoplakin, plakophilin-2, and *DSG2*) for mutations in *DSC2*. Informed consent was obtained from all participating individuals. The study was approved by the relevant hospital ethics committee. Clinical evaluation was performed as described elsewhere,<sup>13</sup>

From the Department of Medicine, University College London, and University College London Hospitals Trust, London

Received August 4, 2006; accepted for publication September 6, 2006; electronically published September 27, 2006.

Address for correspondence and reprints: Dr. William J. McKenna, The Heart Hospital, University College London Hospitals Trust, 16-18 Westmoreland Street, London W1G 8PH, United Kingdom. E-mail: william.mckenna@uclh.org

*Am. J. Hum. Genet.* 2006;79:978–984. © 2006 by The American Society of Human Genetics. All rights reserved. 0002-9297/2006/7905-0021\$15.00

according to the International Task Force of the European Society of Cardiology and International Society and Federation of Cardiology (ESC/ISFC) diagnostic criteria<sup>27</sup> for ARVD/C and the proposed modified diagnostic criteria.<sup>28</sup> In brief, as determined by their specificity, clinical and genetic features of the disease are divided into major and minor criteria. The presence of two major, one major and two minor, or four minor criteria from different categories is considered diagnostic proof of disease. A set of modified diagnostic criteria were subsequently proposed, to facilitate diagnosis in the setting of familial ARVD/C.<sup>28</sup>

DNA from whole blood and paraffin-embedded tissue (from the family B proband) was extracted using QIAamp DNA mini kits (Qiagen). Primer pairs for all *DSC2* exons were designed from flanking intronic sequences that were based on the published sequence of the two forms of the desmocollin-2 gene (*DSC2a* and *DSC2b* [GenBank accession numbers NM\_024422 and NM\_004949, respectively]) (table 1). PCR amplification was performed using standard protocols (AmpliQ Gold [Applied Biosystems]). PCR products were sequenced in both directions on an Applied Biosystems 3130 Genetic Analyzer, with use of BigDye Terminator chemistry (v3.1), and were analyzed by Seqscape v2.5 software (Applied Biosystems).

Two heterozygous *DSC2* mutations—a deletion and an insertion—were detected in four probands and three family members. Neither mutation was found in 200 white volunteers.

In family A, a deletion of a single nucleotide (1430delC) was detected in exon 10 of *DSC2* in two individuals: the proband (III.1) and her mother (II.2) (fig. 1A). It leads to a frameshift and a premature termination codon at position 480 (M477fsX480). Three family members (III.2, III.3, and III.4) were homozygous for the wild-type sequence.

Affected individuals from families B, C, and D carried an insertion of two bases in exon 17 (2687\_2688insGA) (fig. 1B). This mutation is predicted to generate a termination codon 4 aa residues downstream (E896fsX900).

The proband (III.2) in family B died suddenly at age 15 years. Her postmortem examination showed extensive fibrofatty replacement of the right ventricular myocardium, which is consistent with a diagnosis of ARVD/C. The presence of the E896fsX900 mutation was confirmed in cardiac tissue preserved at postmortem examination. Her father (II.1) and one sister (III.1) also carried this mutation. Her other sister (III.3) declined genetic testing; her clinical evaluation was normal. There is no other family history of premature sudden death.

In family C, the proband (II.2) had diagnostic features of ARVD/C and carried the E896fsX900 mutation. Her brother (II.3) died suddenly at age 40 years, and postmortem findings were consistent with ARVD/C. However, cardiac tissue was not made available for genotyping.

In family D, the proband (II.2) could not be assessed for repolarization/depolarization abnormalities because electrocardiogram (ECG) results indicated that she had a left bundle branch block; therefore, she does not fulfill diag-

**Table 1. Intronic Primer Sequences Used for PCR Amplification and Sequencing of *DSC2***

Exon(s)	Primer Sequence (5'→3')	
	Sense	Antisense
1	AGCAGCGGGCCAGACTGCGCT	GTTTCCTCTGCACCCTAGGCG
2	GCCTTTTATGTGTATATCAT	TTCCTTTTATGGCTGTGTAG
3	CACGTGCATACATTACTGTTAA	GTAATGTTGATTACGTCTGAAG
4	GTCATTGTTAATGTTTGAGAA	ATAATGGTAAGAGATGGAAC
5	ATAGATGAAAGCTCTGCTGAA	AAATGGCCAAGCATCATCATT
6	TGAATTTGAAGCATACTCAT	TGTATGAATTGAAACACAGTT
7	ATAAAGGGAACATAGAACATGT	GAGTTATACAGTACTATTGAA
8	GGAGTGTAAGTAAGATTTCAA	CAGAGATGTGCATATTAACAA
9	GTGCTAGGGTTTCAAATCATG	CTTCCATTAATTTAGCATGC
10	GCATTGCCAATATTAATGA	GCTAAATTATAAACGTAAC
11	GCAGTGGCATAAGGTACTTACC	AACAGAGTGCATGTATCCAGC
12	TCAGTGCATCTTTGTGGTGA	AGTATCGCAGACATCCTGATG
13	AGAAGAAATCAGTGACATTGTA	CTTGAAAGTTACTTTAAAGGGT
14	TGTGTGATTAACCATTTGACA	TACGCATTATAAGCGAATTCAT
15	GGCATTATCCGCTTGATGTTGTC	CAATTAGTAGAATTAGTAGATTC
16 and 17 <sup>a</sup>	GCTATACTGAATTTATAGTGTGAT	TAAAGTCATAAGCCACTGGCTT

<sup>a</sup> Exons 16 and 17 were amplified as a single PCR amplicon.

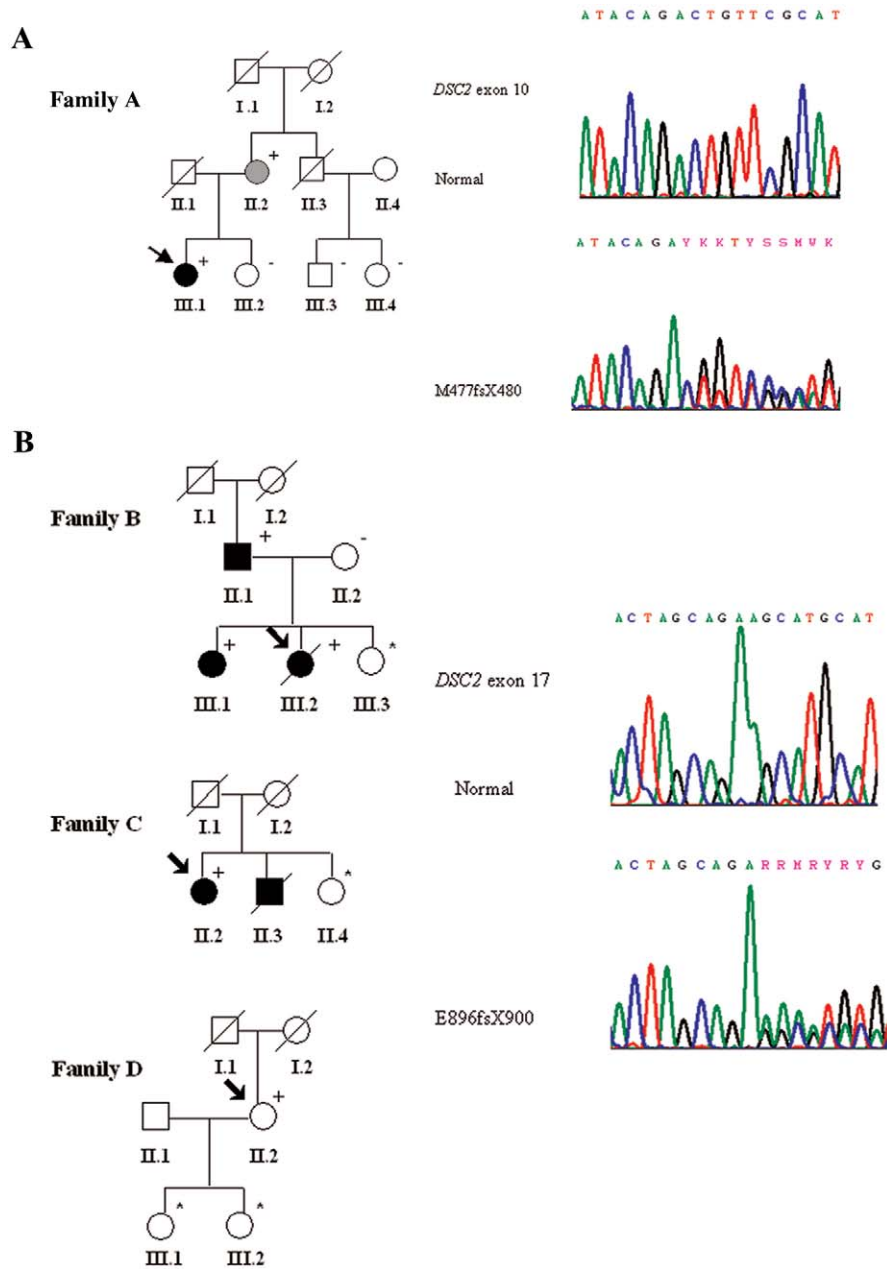
nostic criteria for ARVD/C. Her father (I.1) had a premature sudden death at age 30 years, but no postmortem examination was performed. The proband's daughters (III.1 and III.2) declined clinical and genetic evaluation.

In all families, individuals who were homozygous for the wild-type alleles were normal on clinical evaluation. Clinical data about mutation carriers are summarized in table 2.

For the first time, to our knowledge, we describe mutations in the desmocollin-2 gene in families with ARVD/C. Interestingly, to date, no mutations in human desmocollin isoforms have been reported. Of the three isoforms, only *DSC1* has been implicated in human disease, since it was identified as an autoantigen for subcorneal pustular dermatosis-type IgA pemphigous.<sup>29</sup> This is in marked contrast with the involvement of desmoglein isoforms in several diseases, including ARVD/C, striate palmoplantar keratoderma, and autoimmune disorders.<sup>16,17,30–32</sup> However, animal studies have shown that *Dsc1*-null mice exhibit severe skin abnormalities due to loss of cell-cell adhesion.<sup>33</sup>

Desmosomal cadherins, through their well-documented adhesive functions, regulate desmosomal adhesion and formation and are also involved in tissue differentiation.<sup>34</sup> The desmocollin-2 protein comprises the extracellular amino terminal EC1–EC4 domains, an extracellular anchor domain (EA), a short transmembrane domain (TM), an intracellular anchor domain (IA), and the intracellular cadherin-binding domain (ICS) (fig. 2).

The two *DSC2* mutations described in this study are considered to be pathogenic, since they result in frameshifts and premature termination codons. In particular, in family A, mutation M477fsX480 is in the fourth extracellular cadherin repeat (EC4) and is predicted to truncate approximately one-half of the desmocollin-2 protein, with loss of the transmembrane and cytoplasmic components.



**Figure 1.** Pedigrees of families A–D and sequence electropherograms of *DSC2* showing mutant sequences compared with a normal control. Blackened symbols indicate individuals fulfilling ESC/ISFC diagnostic criteria for ARVD/C and/or those confirmed as affected at postmortem examination<sup>27</sup>; a gray symbol indicates individuals fulfilling the modified diagnostic criteria only<sup>28</sup>; white symbols indicate unaffected individuals; slanted bars indicate deceased individuals; plus (+) and minus (–) signs indicate the presence or absence, respectively, of a mutation in *DSC2*; an asterisk (\*) indicates an individual who declined clinical evaluation and/or genetic testing; squares indicate males; circles indicate females. The index patient in each family is marked with an arrow. *A*, Family A. Affected individuals carry the M477fsX480 mutation. *B*, Families B–D. Affected individuals carry the E896fsX900 mutation. In family D, individual II.2 does not fulfill diagnostic criteria, because she has predominantly left ventricular disease.

It can be speculated that this leads to a completely non-functional mutant protein; however, it is more likely that this deletion causes *DSC2* haploinsufficiency by nonsense-mediated mRNA decay.

Alternative splicing of exon 16 produces two *DSC2* isoforms (*DSC2a* [long form] and *DSC2b* [short form]) with

*DSC2b* lacking the entire ICS.<sup>24</sup> In contrast, in *DSC2a*, exon 17 encodes the ICS domain, which displays a high degree of amino acid homology among various desmosomal and nondesmosomal cadherins. It is believed that the binding site to plakoglobin is located within this functionally important domain.<sup>35</sup> In particular, the last 37 aa residues in

**Table 2. Clinical Data for ARVD/C-Affected Families**

Family and Subject	Age (in years)		Symptom(s)	Family History	Abnormalities			Arrhythmia	No. of Diagnostic Criteria (Major/Minor)	Genotype
	Current	At Diagnosis			Depolarization/Conduction	Repolarization	Right Ventricle Structure			
<b>A:</b>										
III.1	43	42	Syncope	—	Minor	—	Major	Minor	1/2 <sup>a</sup>	M477fsX480
II.2	78	—	Palpitations	Minor	—	—	Minor	Minor	0/3 <sup>b</sup>	M477fsX480
<b>B:</b>										
III.2	Deceased	15	Syncope	—	—	Minor	Minor	Minor	1/3 <sup>a</sup>	E896fsX900
II.1	59	59	Palpitations, syncope	Major	Major	—	Minor	—	2/1 <sup>a</sup>	E896fsX900
III.1	19	19	—	Major	—	—	Minor	Minor	1/2 <sup>a</sup>	E896fsX900
III.3	13	—	—	Major	—	—	—	—	1/0	Declined investigation
<b>C:</b>										
II.2	42	42	Palpitations	Major	—	—	Major	Minor	2/1 <sup>a</sup>	E896fsX900
II.3	Deceased	40	Cardiac arrest	—	NP	NP	—	NP	1/0	Cardiac tissue not available
II.4	43	—	—	Major	—	—	—	—	1/0	Declined investigation
<b>D:</b>										
II.2	65	60	Shortness of breath, presyncope, palpitations	Minor	NA	NA	Minor	Minor	0/3 <sup>c</sup>	E896fsX900

NOTE.—A minus sign (—) = absent; NA = not appropriate because of presence, on ECG, of left bundle branch block; NP = not performed.

<sup>a</sup> Fulfills ESC/ISFC criteria for a diagnosis of ARVD/C.<sup>27</sup> For individuals III.2 (family B) and II.3 (family C), disease was confirmed at postmortem examination (major criterion).

<sup>b</sup> Does not fulfill diagnostic criteria but, in the setting of a positive family history, does have features suggestive of ARVD/C and would satisfy the proposed modified criteria.<sup>28</sup>

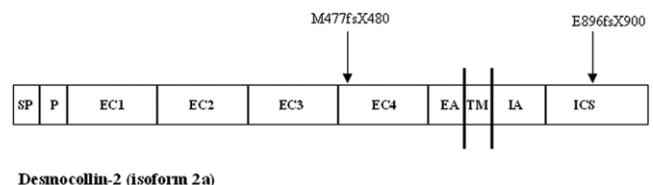
<sup>c</sup> Does not fulfill ESC/ISFC criteria and has predominantly left ventricular disease.

the carboxyl-terminal domain of *DSC2a* are essential for binding plakoglobin. Experiments in epithelial cells have shown that desmocollin mutants lacking this short segment from the C terminus did not have the ability to bind plakoglobin or to effect the formation of the desmosomal plaque and the intermediate filaments' anchorage.<sup>35</sup> Mutation E896fsX900 (in families B–D) is located in exon 17 and would affect the C terminus of *DSC2* by altering 4 aa residues before a termination codon is prematurely introduced. In the absence of functional studies, it is difficult to predict exactly how these two mutations in *DSC2* would affect desmosome formation. However, since desmocollins are crucial in cell adhesion and tissue morphogenesis, it can be speculated that absence of *DSC2* or incorporation of mutant *DSC2* in desmosomes would result in structurally and functionally impaired desmosomes. This would be in agreement with the widely accepted “desmosomal model” hypothesis. It is believed that, under conditions of mechanical stress, impaired desmosome function due to desmosomal gene mutations would lead to detachment and death of cardiac myocytes followed by inflammation and fibrofatty replacement.<sup>5</sup> However, recent data from Garcia-Gras and colleagues on desmoplakin-deficient mice implicate a novel disease mechanism through inhibition of the Wnt/ $\beta$ -catenin signaling network.<sup>36</sup> Clearly, functional studies of *DSC2* mutants are required for the investigation of how mutations in desmocollin-2 may result in an ARVD/C phenotype.

The presence of the E896fsX900 mutation in four families indicates either that this insertion is recurrent in patients with ARVD/C who harbor *DSC2* mutations or that families B–D may have a common founder. However, haplotype analysis with use of microsatellite DNA markers (*D18S847*, *D18S49*, and *D18S457*) in close proximity to the *DSC2* locus in individuals carrying E896fsX900 identified no allele sharing (data not shown). This data would suggest that E896fsX900 is a recurrent mutation.

Although desmocollin-2 expression in tissues is widespread, individuals carrying a *DSC2* mutation did not show clinical evidence of hair or skin abnormalities. This is consistent with previous studies in which only a cardiac phenotype was present in patients with plakophilin-2 and *DSG2* mutations.<sup>12–17</sup> Therefore, it seems likely that *DSC1* and *DSC3* compensates for a dysfunctional *DSC2* isoform in epithelial cells but not in cardiac myocytes, where only *DSC2* is expressed.<sup>23</sup>

All mutation carriers in our families have clinical features of ARVD/C (table 2). However, disease penetrance is incomplete; consequently, not all our patients fulfill the ARVD/C diagnostic criteria set out by the International Task Force of the ESC/ISFC. Our finding is consistent with previous findings in patients with ARVD/C caused by mutations in desmoplakin, plakophilin-2, and *DSG2*.<sup>9,13,17</sup> Furthermore, since the publication of the current diagnostic criteria, it has become clear that these criteria cannot be effectively applied to relatives of definitely affected pro-



Desmocollin-2 (isoform 2a)

**Figure 2.** Schematic structure of desmocollin-2 (isoform 2a). SP = signal peptide; P = propeptide. The positions of the M477fsX480 and E896fsX900 mutations are marked.

bands who have features of cardiomyopathy on clinical evaluation. This issue was specifically addressed by Hamid and colleagues, who found that the presence of certain abnormalities was, alone, sufficient to make a diagnosis of ARVD/C in a subject with a definitely affected relative.<sup>28</sup> Application of these criteria to the relatives, as detailed in table 2, enables a more realistic assessment of cosegregation.

In ARVD/C, the classic presentation is with right ventricular involvement, with an apparent progression to left ventricular involvement. It is striking that five of seven individuals in our group (II.2 and III.1 in family A, III.2 in family B, II.3 in family C, and II.2 in family D) had evidence of significant left ventricular involvement that was more obvious than the right ventricular disease in two individuals. Interestingly, in family A, the ECG of the proband is suggestive of left ventricular predominance, but the imaging studies demonstrate more-extensive right ventricular involvement. The same phenomenon has been reported elsewhere in a proband with a desmoplakin mutation.<sup>9</sup> The presence of left ventricular involvement in patients with *DSC2* mutations is consistent with previous findings in ARVD/C associated with mutations in plakoglobin, desmoplakin, and *DSG2* (27%, 27%, and 40% of mutation carriers, respectively, had ECG and/or imaging evidence of abnormalities in the left ventricle).<sup>9,16,37</sup> The ESC/ISFC criteria do not allow for left ventricular disease, but our results would suggest that *DSC2* mutations may be more frequently associated with a predominately left ventricular phenotype of ARVD/C or an arrhythmogenic left ventricular cardiomyopathy without significant right ventricular involvement. However, since this study is limited by the small number of mutation carriers, this finding will need to be confirmed in larger kindreds in future studies.

In conclusion, for the first time, we have identified mutations in desmocollin-2 in patients and family members with ARVD/C. This finding is consistent with the hypothesis that *DSC2* is the fifth desmosomal gene causing ARVD/C and provides further evidence that ARVD/C is a disease of cell adhesion.

## Acknowledgments

This work was supported by the British Heart Foundation and the European Commission 5th Framework Program ARVC/D grant QLG1-CT-2000-01091. We thank the patients and family members for taking part in this study.

## Web Resources

Accession numbers and URLs for data presented herein are as follows:

GenBank, <http://www.ncbi.nlm.nih.gov/Genbank/> (for *DSC2a* [accession number NM\_024422] and *DSC2b* [accession number NM\_004949])

Online Mendelian Inheritance in Man (OMIM), <http://www.ncbi.nlm.nih.gov/Omim/> (for ARVD/C)

## References

- Marcus FI, Fontaine GH, Guiraudon G, Frank R, Laurenceau JL, Malergue C, Grosogeat Y (1982) Right ventricular dysplasia: a report of 24 adult cases. *Circulation* 65:384–398
- Corrado D, Basso C, Thiene G (2000) Arrhythmogenic right ventricular cardiomyopathy: diagnosis, prognosis, and treatment. *Heart* 83:588–595
- Fontaine G, Fontaliran F, Hebert JL, Chemla D, Zenati O, Lecarpentier Y, Frank R (1999) Arrhythmogenic right ventricular dysplasia. *Annu Rev Med* 50:17–35
- Corrado D, Fontaine G, Marcus FI, McKenna WJ, Nava A, Thiene G, Wichter T, Study Group on Arrhythmogenic Right Ventricular Dysplasia/Cardiomyopathy of the Working Groups on Myocardial and Pericardial Disease and Arrhythmias of the European Society of Cardiology and of the Scientific Council on Cardiomyopathies of the World Heart Federation (2000) Arrhythmogenic right ventricular cardiomyopathy: need for an international registry. *Circulation* 101:E101–E106
- Sen-Chowdhry S, Syrris P, McKenna WJ (2005) Genetics of right ventricular cardiomyopathy. *J Cardiovasc Electrophysiol* 16:927–935
- McKoy G, Protonotarios N, Crosby A, Tsatsopoulou A, Anastakis A, Coonar A, Norman M, Baboonian C, Jeffery S, McKenna WJ (2000) Identification of a deletion in plakoglobin in arrhythmogenic right ventricular cardiomyopathy with palmoplantar keratoderma and woolly hair (Naxos disease). *Lancet* 355:2119–2124
- Rampazzo A, Nava A, Malacrida S, Beffagna G, Bauce B, Rossi V, Zimbello R, Simionati B, Basso C, Thiene G, Towbin JA, Danieli GA (2002) Mutation in human desmoplakin domain binding to plakoglobin causes a dominant form of arrhythmogenic right ventricular cardiomyopathy. *Am J Hum Genet* 71:1200–1206
- Norman M, Simpson M, Mogensen J, Shaw A, Hughes S, Syrris P, Sen-Chowdhry S, Rowland E, Crosby A, McKenna WJ (2005) Novel mutation in desmoplakin causes arrhythmogenic left ventricular cardiomyopathy. *Circulation* 112:636–642
- Bauce B, Basso C, Rampazzo A, Beffagna G, Daliento L, Frigo G, Malacrida S, Settimo L, Danieli G, Thiene G, Nava A (2005) Clinical profile of four families with arrhythmogenic right ventricular cardiomyopathy caused by dominant desmoplakin mutations. *Eur Heart J* 26:1666–1675
- Norgett EE, Hatsell SJ, Carvajal-Huerta L, Cabezas JC, Common J, Purkis PE, Whittock N, Leigh IM, Stevens HP, Kelsell DP (2000) Recessive mutation in desmoplakin disrupts desmoplakin-intermediate filament interactions and causes dilated cardiomyopathy, woolly hair and keratoderma. *Hum Mol Genet* 9:2761–2766
- Alcalai R, Metzger S, Rosenheck S, Meiner V, Chajek-Shaul T (2003) A recessive mutation in desmoplakin causes arrhythmogenic right ventricular dysplasia, skin disorder, and woolly hair. *J Am Coll Cardiol* 42:319–327
- Gerull B, Heuser A, Wichter T, Paul M, Basson CT, McDermott DA, Lerman BB, Markowitz SM, Ellinor PT, MacRae CA, Peters S, Grossmann KS, Michely B, Sasse-Klaassen S, Birchmeier W, Dietz R, Breithardt G, Schulze-Bahr E, Thierfelder L (2004) Mutations in the desmosomal protein plakophilin-2 are common in arrhythmogenic right ventricular cardiomyopathy. *Nat Genet* 36:1162–1164
- Syrris P, Ward D, Asimaki A, Sen-Chowdhry S, Ebrahim HY, Evans A, Hitomi N, Norman M, Pantazis A, Shaw AL, Elliott PM, McKenna WJ (2006) Clinical expression of plakophilin-2 mutations in familial arrhythmogenic right ventricular cardiomyopathy. *Circulation* 113:356–364
- Dalal D, Molin LH, Piccini J, Tichnell C, James C, Bomma C, Prakasa K, Towbin JA, Marcus FI, Spevak PJ, Bluemke DA, Abraham T, Russell SD, Calkins H, Judge DP (2006) Clinical features of arrhythmogenic right ventricular dysplasia/cardiomyopathy associated with mutations in plakophilin-2. *Circulation* 113:1641–1649
- van Tintelen JP, Entius MM, Bhuiyan ZA, Jongbloed R, Wiesfeld AC, Wilde AA, van der Smagt J, Boven LG, Mannens MM, van Langen IM, Hofstra RM, Otterspoor LC, Doevendans PA, Rodriguez LM, van Gelder IC, Hauer RN (2006) Plakophilin-2 mutations are the major determinant of familial arrhythmogenic right ventricular dysplasia/cardiomyopathy. *Circulation* 113:1650–1658
- Pilichou K, Nava A, Basso C, Beffagna G, Bauce B, Lorenzon A, Frigo G, Vettori A, Valente M, Towbin J, Thiene G, Danieli GA, Rampazzo A (2006) Mutations in desmoglein-2 gene are associated with arrhythmogenic right ventricular cardiomyopathy. *Circulation* 113:1171–1179
- Awad MM, Dalal D, Cho E, Amat-Alarcon N, James C, Tichnell C, Tucker A, Russell SD, Bluemke DA, Dietz HC, Calkins H, Judge DP (2006) *DSG2* mutations contribute to arrhythmogenic right ventricular dysplasia/cardiomyopathy. *Am J Hum Genet* 79:136–142
- Tiso N, Stephan DA, Nava A, Bagattin A, Devaney JM, Stanchi F, Larderet G, Brahmabhatt B, Brown K, Bauce B, Muriago M, Basso C, Thiene G, Danieli GA, Rampazzo A (2001) Identification of mutations in the cardiac ryanodine receptor gene in families affected with arrhythmogenic right ventricular cardiomyopathy type 2 (ARVD2). *Hum Mol Genet* 10:189–194
- Bauce B, Rampazzo A, Basso C, Bagattin A, Daliento L, Tiso N, Turrini P, Thiene G, Danieli GA, Nava A (2002) Screening for ryanodine receptor type 2 mutations in families with effort-induced polymorphic ventricular arrhythmias and sudden death: early diagnosis of asymptomatic carriers. *J Am Coll Cardiol* 40:341–349
- Beffagna G, Occhi G, Nava A, Vitiello L, Ditadi A, Basso C, Bauce B, Carraro G, Thiene G, Towbin JA, Danieli GA, Rampazzo A (2005) Regulatory mutations in transforming growth factor- $\beta$ 3 gene cause arrhythmogenic right ventricular cardiomyopathy type 1. *Cardiovasc Res* 65:366–373
- Huber O (2003) Structure and function of desmosomal pro-

- teins and their role in development and disease. *Cell Mol Life Sci* 60:1872–1890
22. Garrod DR, Merritt AJ, Nie Z (2002) Desmosomal cadherins. *Curr Opin Cell Biol* 14:537–545
  23. Nuber UA, Schäfer S, Schmidt A, Koch PJ, Franke WW (1995) The widespread human desmocollin Dsc2 and tissue-specific patterns of synthesis of various desmocollin subtypes. *Eur J Cell Biol* 66:69–74
  24. Greenwood MD, Marsden MD, Cowley CM, Sahota VK, Buxton RS (1997) Exon-intron organization of the human type 2 desmocollin gene (DSC2): desmocollin gene structure is closer to “classical” cadherins than to desmogleins. *Genomics* 44:330–335
  25. Syed SE, Trinnaman B, Martin S, Major S, Hutchinson J, Magee AI (2002) Molecular interactions between desmosomal cadherins. *Biochem J* 362:317–327
  26. Troyanovsky RB, Chitaev NA, Troyanovsky SM (1996) Cadherin binding sites of plakoglobin: localization, specificity and role in targeting to adhering junctions. *J Cell Sci* 109:3069–3078
  27. McKenna WJ, Thiene G, Nava A, Fontaliran F, Blomstrom-Lundqvist C, Fontaine G, Camerini F, Task Force of the Working Group Myocardial and Pericardial Disease of the European Society of Cardiology and of the Scientific Council on Cardiomyopathies of the International Society and Federation of Cardiology (1994) Diagnosis of arrhythmogenic right ventricular dysplasia/cardiomyopathy. *Br Heart J* 71:215–218
  28. Hamid MS, Norman M, Quraishi A, Firoozi S, Thaman R, Gimeno JR, Sachdev B, Rowland E, Elliott PM, McKenna WJ (2002) Prospective evaluation of relatives for familial arrhythmogenic right ventricular cardiomyopathy/dysplasia reveals a need to broaden diagnostic criteria. *J Am Coll Cardiol* 40:1445–1450
  29. Hashimoto T, Kiyokawa C, Mori O, Miyasato M, Chidgey MA, Garrod DR, Kobayashi Y, Komori K, Ishii K, Amagai M, Nishikawa T (1997) Human desmocollin 1 (Dsc1) is an autoantigen for the subcorneal pustular dermatosis type of IgA pemphigus. *J Invest Dermatol* 109:127–131
  30. Amagai M, Klaus-Kovtun V, Stanley JR (1991) Autoantibodies against a novel epithelial cadherin in pemphigus vulgaris, a disease of cell adhesion. *Cell* 67:869–877
  31. Hunt DM, Rickman L, Whittock NV, Eady RA, Simrak D, Dopping-Hepenstal PJ, Stevens HP, Armstrong DK, Hennies HC, Kuster W, Hughes AE, Arnemann J, Leigh IM, McGrath JA, Kelsell DP, Buxton RS (2001) Spectrum of dominant mutations in the desmosomal cadherin desmoglein 1, causing the skin disease striate palmoplantar keratoderma. *Eur J Hum Genet* 9:197–203
  32. Moss C, Martinez-Mir A, Lam H, Tadin-Strapps M, Kljuic A, Christiano AM (2004) A recurrent intragenic deletion in the desmoglein 4 gene underlies localized autosomal recessive hypotrichosis. *J Invest Dermatol* 123:607–610
  33. Chidgey M, Brakebusch C, Gustafsson E, Cruchley A, Hail C, Kirk S, Merritt A, North A, Tselepis C, Hewitt J, Byrne C, Fassler R, Garrod D (2001) Mice lacking desmocollin 1 show epidermal fragility accompanied by barrier defects and abnormal differentiation. *J Cell Biol* 155:821–832
  34. Garrod DR, Merritt AJ, Nie Z (2002) Desmosomal adhesion: structural basis, molecular mechanism and regulation. *Mol Membr Biol* 19:81–94
  35. Troyanovsky SM, Troyanovsky RB, Eshkind LG, Leube RE, Franke WW (1994) Identification of amino acid sequence motifs in desmocollin, a desmosomal glycoprotein, that are required for plakoglobin binding and plaque formation. *Proc Natl Acad Sci USA* 91:10790–10794
  36. Garcia-Gras E, Lombardi R, Giocondo MJ, Willerson JT, Schneider MD, Khoury DS, Marian AJ (2006) Suppression of canonical Wnt/ $\beta$ -catenin signaling by nuclear plakoglobin recapitulates phenotype of arrhythmogenic right ventricular cardiomyopathy. *J Clin Invest* 116:2012–2021
  37. Protonotarios N, Tsatsopoulou A, Anastasakis A, Sevdalis E, McKoy G, Stratos K, Gatzoulis K, Tentolouris K, Spiliopoulou C, Panagiotakos D, McKenna W, Toutouzas P (2001) Genotype-phenotype assessment in autosomal recessive arrhythmogenic right ventricular cardiomyopathy (Naxos disease) caused by a deletion in plakoglobin. *J Am Coll Cardiol* 38:1477–1484